

ORIGINAL RESEARCH REPORT

Novel 755-nm diode laser vs. conventional 755-nm scanned alexandrite laser: Side-by-side comparison pilot study for thorax and axillary hair removal

UWE PAASCH¹, JUSTINUS A. WAGNER¹ & HARTMUT W. PAASCH²

¹Department of Dermatology, Venereology and Allergology, University of Leipzig, Leipzig, Saxony, Germany and
²Practice of Dermatology, Allergology, Lasers and Aesthetics, Saxony, Germany

Abstract

Background: Alexandrite (755 nm) and diode lasers (800–810 nm) are commonly used for hair removal. The alexandrite laser technology is somewhat cumbersome whereas new diode lasers are more robust. Recently, alexandrite-like 755 nm wavelength diodes became available. **Objectives:** To compare the efficacy, tolerability, and subject satisfaction of a 755 nm diode laser operated in conventional (HR) and non-conventional in-motion (SHR) modes with a conventional scanned alexandrite 755 nm laser for chest and axillary hair removal. **Materials and methods:** A prospective, single-center, proof of principle study was designed to evaluate the safety, efficacy and handling of a 755 nm diode laser system in comparison to a standard alexandrite 755 nm scanning hair removal laser. **Results:** The new 755 nm diode is suitable to be used in SHR and HR mode and has been tested for its safety, efficacy and handling in a volunteer with success. Overall, both systems showed a high efficacy in hair reduction (88.8% 755 nm diode laser vs. 77.7% 755 nm alexandrite laser). Also, during the study period, no severe adverse effects were reported. **Conclusion:** The new 755 nm diode laser is as effective and safe as the traditional 755 nm alexandrite laser. Additionally, treatment with the 755 nm diode laser with HR and SHR modes was found to be less painful.

Key Words: 755 nm, diode, hair removal, laser, selective photothermolysis

Introduction

Laser hair removal is one of the most often applied cosmetic procedures (1). The theory of selective photothermolysis and its further development ensures the efficacy and safety of lasers for that indication (2,3). On top of this it aims for the permanent elimination of the dermal papilla and/or the stem cells within the bulge region. Terminal hair follicles are selectively damaged if a wavelength absorbed by melanin is applied to heat the hair structure. To date a variety of wavelengths are at hand and long-lasting removal of hair can be achieved to some extent. However, the concept of laser hair removal is still being improved (4). Notably, efficacy and side effects are major factors with room for improvement. In terms of efficacy and safety, the alexandrite laser and the long-pulsed 810 nm diode laser are the most popular systems available and suitable for skin types I–IV, according to FDA approvals.

Based on published evidence, the traditional flash lamp pulsed alexandrite laser remains still the almost ideal system having some advance to the diode lasers (5). However, the technology of flash lamp pulsed systems was developed many years ago and next to efficacy other criteria may be critically for physicians and patient. Namely the need to exchange the flash lamps regularly, type of cooling, the problems of fragile transmission systems and bulky scanner do play a role. Finally, the concept of using low fluencies at high average power with a multiple pass in-motion technique has been introduced for the 810 nm diode lasers leading to a dramatic decrease in therapy related pain, less discomfort and good efficacy over 12 month (6–9).

Recently, technical developments have high power laser diodes emitting at 755 nm made available. As a natural consequence they have made their way instantly into a new laser system.

Correspondence: Uwe Paasch, MD, PhD, Department of Dermatology, Venereology and Allergology, University of Leipzig, Philipp-Rosenthal-Strasse 23, 04103 Leipzig, Saxony, Germany. E-mail: uwe.paasch@medizin.uni-leipzig.de

(Received 20 August 2014; accepted 5 January 2015)

ISSN 1476-4172 print/ISSN 1476-4180 online © 2015 Taylor & Francis Group, LLC
DOI: 10.3109/14764172.2015.1007062

Here we report for the first time clinical proof of a newly developed 755 nm diode laser with integrated sapphire contact cooling for safety and efficacy in comparison to a conventional-scanning flash lamp pulsed alexandrite laser for removing axillary and chest hair.

Materials and methods

A prospective, single-center, proof of principle study was designed to evaluate the safety, efficacy and handling of a newly developed 755 nm diode laser system (Soprano ICE, Alma Lasers GmbH, Nürnberg, Germany) in comparison to a standard alexandrite 755 nm scanning hair removal laser (ARION, Alma Lasers GmbH, Nürnberg, Germany). The study protocol conformed to the ethical guidelines of the 1975 Declaration of Helsinki.

Laser systems

The classical alexandrite flash lamp pulsed solid state single-spot scan laser (ARION, Alma Lasers GmbH, Nürnberg, Germany) has a wavelength of 755 nm, with adjustable pulse duration of 5 to 140 ms, fluence of up to 100 J/cm², and round spot size of 6 to 16 mm in diameter. To prevent epidermal damage, an air-cooling system (Zimmer Medizinsysteme GmbH, Cryo6, Neu Ulm, Germany) can be attached directly to the hand piece. The system is equipped with a scanner enabling the operator to treat larger areas by placing pulses in a pseudo-random fashion.

The newly developed 755 nm diode laser (Soprano ICE, Alma Lasers GmbH, Nürnberg, Germany) emits at a wavelength of 755 nm, with a pulse duration of 20 ms and a pulse repetition rate up to 10 Hz using the in-motion technique (super hair removal mode, SHR) or up to 20–150 ms in classical hair removal mode (hair removal, HR), a fluence range of 1–20 J/cm² in SHR or 1–120 J/cm² in HR, and a spot sizes of 1.5 cm². Additionally, an integrated thermo-electro contact cooling system using a sapphire glass window enables skin protection during the treatment.

Patients

To prove the safety and efficacy a voluntary adult male patient (age 47 years, Fitzpatrick skin type II, dark brown coarse hair) was selected and treated, once written consent to participate in the trial to undergo axillary and chest hair removal with two different laser systems was given.

Treatment protocols

The study subject was instructed to shave his hair the day before each laser treatment. The patient

received a total of 4 treatments at 4–6 week intervals. No topical or local anesthesia was administered along with the laser treatment. To reduce side effects and patient discomfort, the contact-cooling system or the air-cooling system (level 5) was used during treatment with each laser. All laser treatments were performed by a blinded board-certified dermatologist. After treatment, the subjects were instructed to cool the treated areas on demand with cooling packs.

Evaluation of safety and efficacy of the 755 nm diode laser SHR mode

To test the safety and efficacy of the newly developed 755 nm diode laser with SHR technique/mode as a potential substitute of solid state flash lamp pumped alexandrite lasers, the hair at the breast of the study subject was treated.

With its high average power (up to 150 W) the SHR technique of the 755 nm diode laser involves sweeping the laser hand piece (In-motion) inside a 120 W area until total emitted energy of 8 kJ is reached as an end-point (1 kJ is equivalent to 1.000 J). The in-motion technique enables to control the thermogenic intensity of the laser skin-hair interaction, controlling the pain, erythema, inflammation and other side effects during the following period of 24 h. Then, the contra-lateral site side was treated with the same laser system using same parameters. From the second laser treatment on the whole chest has been subjected to hair removal at each of the following three laser sessions using 8 J/cm² until 8 kJ were applied and equally distributed on an area of 10 × 15 cm (Figure 1).

Comparison of 755-nm diode HR mode and scanned 755 nm alexandrite laser hair removal

During each treatment session, the right axilla was treated at once with the 755 nm diode laser in the HR mode with a fluence of 20 J/cm², a pulse duration of 20 ms, a spot size of 1.5 cm², 20% overlap, 12 pulses, 1 pass, contact cooling, while the left axilla was treated with 755 nm alexandrite laser using a fluence of 20 J/cm², a pulse duration of 20 ms, a spot size of 10 mm, 24–34 pulses, 577–769 J together with on-time air flow cooling (Figure 2).

Clinical assessments

Axillary and chest hair density was assessed at baseline, before each treatment and at each follow-up visit using the automatic TrichoScan[®] (Freiburg, Germany) analysis according to the manufacturer's instructions. TrichoScan[®] is a reliable and validated software program for quantifying hair growth that uses epilumines-

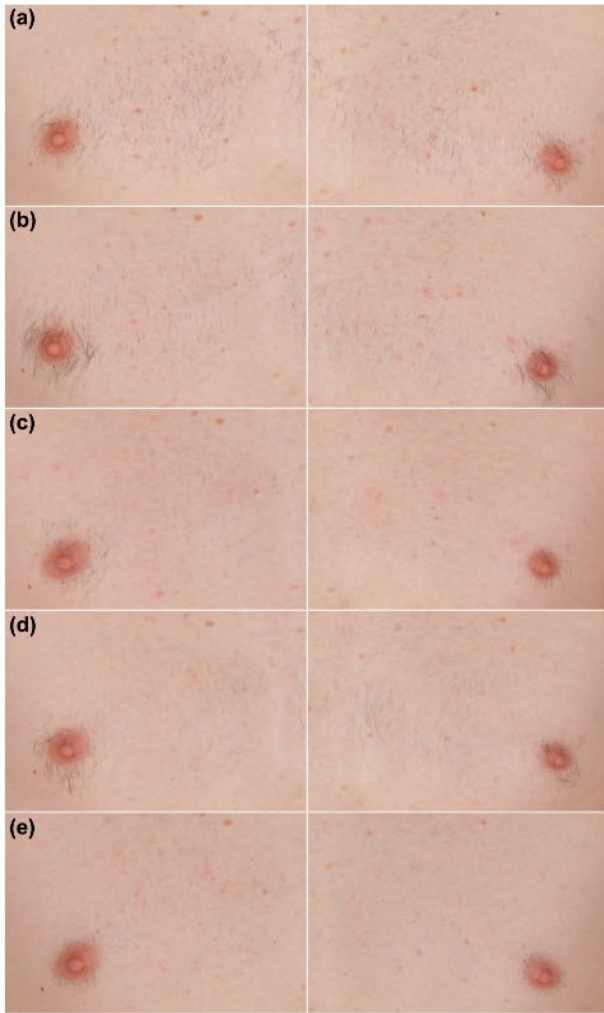


Figure 1. Clinical picture of treatment results of the 755 nm diode laser in SHR mode using 6–8 J/cm² up to 8 kJ/15 cm² at following time points: a) Baseline, b) 6 weeks post 1st treatment; c) 4 weeks post 2nd TX = Pre-3rd treatment; d) 4 weeks post 3rd TX = Pre-4th treatment; e) 4 weeks post 4th TX = Pre-5th treatment.

cence microscopy with automatic digital image analysis. Indeed, the intra- and interclass reliability for TrichoScan[®] in the assessment of hair thickness as well as hair density is over 90% (10). The video camera of the Dermogenius Ultra system (DermaScan GmbH, Regensburg, Germany) was used to capture ultra-high density (2592 × 1944 Pixel) images of the axilla with 12-fold magnification, allowing for analysis of an area of 0.592 cm². The images were then loaded onto a computer, and the TrichoScan[®] software was used to analyze hair density (n/cm²). Perifollicular edema and erythema were also documented by the Dermoscope system. Pain, perifollicular edema, and erythema were quantified by the physician using visual analog scales (1–10).

Results

This pilot study was conducted from 8/2013–1/2014. Overall, the new concept of a 755 nm diode laser suitable to be used in SHR and HR mode equipped

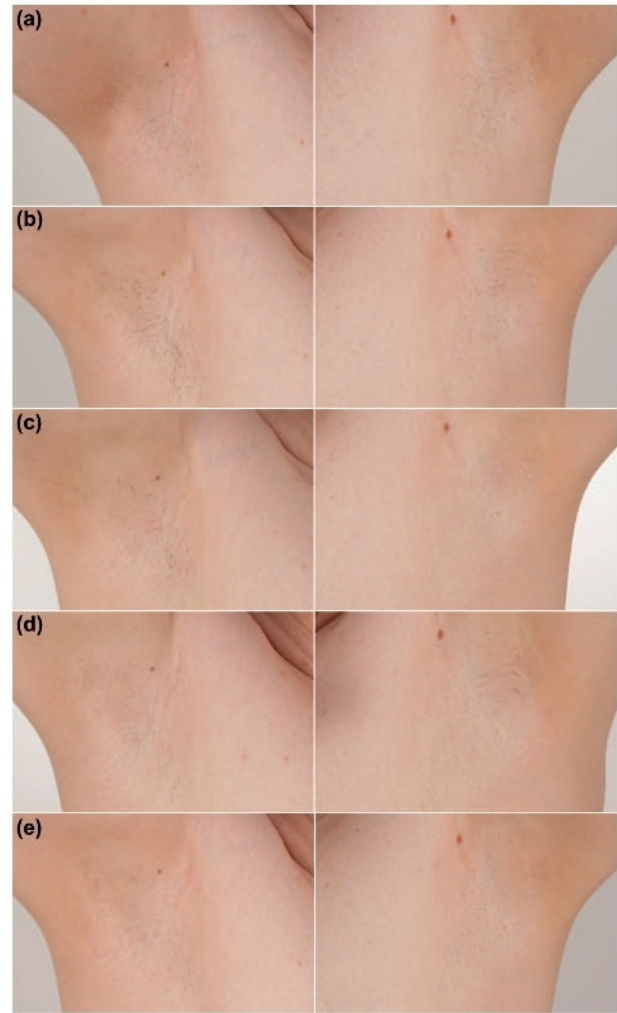


Figure 2. Clinical picture of treatment results of the 755 nm diode laser in HR mode using contact cooling, 20 J/cm², 20 ms, 12 pulses, 1 pass in comparison to a 755 nm alexandrite laser using air flow cooling, a fluence of 20 J/cm², a pulse duration of 20 ms, a spot size of 10 mm, scanned 1–2 passes: a) Baseline, b) 6 weeks post 1st treatment; c) 4 weeks post 2nd TX = Pre-3rd treatment; d) 4 weeks post 3rd TX = Pre-4th treatment; e) 4 weeks post 4th TX = Pre-5th treatment.

with a powerful contact cooling has been tested for its safety, efficacy and handling in a volunteer with success.

Evaluation of safety and efficacy of the 755 nm diode laser SHR mode

The treatment results of the 755 nm diode laser in SHR mode using 6–8 J/cm² up to 8 kJ/150 cm² are given in Table I. Overall after 4 weeks post 4th treatment 91.6% hair reduction was visible. During the study period, no severe adverse events were reported.

The patients' evaluation of treatment-related pain using a visual analog scale (0, no pain; 10, intolerable pain) did not vary during the course of the treatments (2.39 ± 2.44) using the 755 nm SHR

Table I. Treatment results of the 755 nm diode laser in SHR mode using 6–8 J/cm² up to 8 kJ/15 cm².

Time point	Chest right	Chest left	Mean	Reduction [%]
Baseline	18	18	18	
2 weeks post 1st TX	10	14	12	33.3
4 weeks post 1st TX	9	8	8.5	52.7
6 weeks post 1st TX	7	5	6	66.6
Pre-2nd treatment				
4 weeks post 2nd TX	8	8	8	55.5
Pre-3rd treatment				
4 weeks post 3rd TX	4	3	3.5	80.5
Pre-4th treatment				
4 weeks post 4th TX	1	2	1.5	91.6

mode. Pain assessment 1 h after the procedure revealed only very mild heat sensations. Later on there were no other reports of pain or discomfort.

Comparison of 755 nm diode HR mode and scanned 755 nm alexandrite laser hair removal

The treatment settings used to compare the 755 nm diode laser in HR mode with the solid state flash lamp pumped alexandrite laser to remove axillary hair are given in Table II. The results of the 755 nm diode laser in HR mode using contact cooling, a fluence of 20 J/cm², pulse duration of 20 ms, 12 pulses, 1 pass, spot size of 1.5 cm², in comparison to a 755 nm alexandrite laser using air flow cooling, a fluence of 20 J/cm², pulse duration of 20 ms, scanned in 1–2 passes, spot size of 10 mm, are presented in Table III.

Overall, both systems showed a high efficacy in hair reduction (88.8% 755 nm diode laser vs. 77.7% 755 nm alexandrite laser), with no short time worsening of the symptoms (e.g., paradoxical hair growth). Also, during the study period, no severe adverse effects were reported.

The treatment was performed using the alexandrite scanned laser at 755 nm at the left axilla and the 755 nm diode laser at the contra lateral axilla, pain was reported to be different (2.39 ± 2.44 755 nm diode laser vs. 3.18 ± 1.56 755 nm alexandrite laser).

Discussion

Since its introduction in 1995, laser hair removal has proven to be a superior and more permanent solution

for unwanted hair compared to other techniques (11–13), becoming the third most common elective cosmetic procedure in the United States¹. Although a number of lasers and non-laser light sources have been developed for purposes of hair removal, the 755 nm alexandrite and 800–810 nm diode lasers remain common options for hair removal among individuals with Fitzpatrick skin types I–IV (14). Based on published evidence, the traditional flash lamp pulsed alexandrite laser still remains the almost ideal system having some advance to the diode lasers (5).

Recently the application of low fluencies at high average power with a multiple pass in-motion technique using 810 nm diode lasers has been shown to decrease the pain, and discomfort while keeping a good efficacy over 12 month (6–9). Lately, high power laser diodes emitting at 755 nm are at hand and have made their way instantly into a new laser system. Here we present the first prospective, single center proof of principle study of a prototype 755 nm diode laser equipped with a sapphire contact cooling investigating its suitability, safety and efficacy in comparison to a conventional scanning alexandrite laser for removing axillary and chest hair.

Hence the system is capable to be used in any of the two modes, the traditional HR mode or the in-motion technique (SHR), both have been tested within this study. To apply those modes either a fixed pulse duration of 20 ms together with a pulse repetition rate up to 10 Hz and a fluence range of 1–20 J/cm² (SHR) or an adjustable pulse duration up to 150 ms and a fluence range 1–120 J/cm² (HR) can be chosen.

The evaluation of safety and efficacy of the 755 nm diode laser in SHR mode revealed a very high efficacy while keeping the well-known absence of intense pain as well as other side effects in SHR mode (6–9). The study showed continued clinical improvement with each successive treatment session, supported by photo documentation and by exact hair counting using TrichoScan analysis. However due to its nature of the study, no follow-up data are at hand so far.

The second part of the study aimed on the comparison of the 755 nm diode laser in HR mode and the traditional scanned 755 nm alexandrite laser in terms of efficacy and safety. As early as 4 weeks after

Table II. Axillae treatment settings of 755 nm diode laser in HR mode versus flash lamp pumped alexandrite laser.

	755 nm diode right axilla	755 nm alexandrite left axilla
Tx1	20 J/cm ² , 20 ms, 12 pulses, 1 pass	20 J/cm ² , 20 ms, 34 pulses, 769 J
Tx2	20 J/cm ² , 20 ms, 12 pulses, 1 pass	20 J/cm ² , 20 ms, 34 pulses, 769 J
Tx3	20 J/cm ² , 20 ms, 12 pulses, 1 pass	20 J/cm ² , 20 ms, 24 pulses, 577 J
Tx4	20 J/cm ² , 20 ms, 12 pulses, 1 pass	20 J/cm ² , 20 ms, 33 pulses, 756 J

¹Cosmetic Surgery National Data Bank 2010. The American Society for Aesthetic Plastic Surgery. Accessed on June 16, 2011 from: http://www.surgery.org/sites/default/files/Stats2010_1.pdf

Table III. Treatment results of the 755 nm diode laser in HR mode using contact cooled 20 J/cm², 20 ms, 12 pulses, 1 pass in comparison to a 755 nm alexandrite laser using air flow cooling, a fluence of 20 J/cm², a pulse duration of 20 ms, a spot size of 10 mm, scanned 1–2 passes.

Date	Axilla right 755 nm diode	Axilla left 755 nm alexandrite	Reduction 755 nm diode	Reduction 755 nm alexandrite
Baseline	9	10		
2 weeks post 1st TX	8	7	11.1	30.0
4 weeks post 1st TX	4	6	44.4	40.0
6 weeks post 1st TX	2	3	77.7	70.0
4 weeks post 2nd TX	3	7	66.6	30.0
Pre-3rd treatment				
4 weeks post 3rd TX	2	2	77.7	77.7
Pre-4th treatment				
4 weeks post 4th TX	1	2	88.8	77.7
Pre-5th treatment				

the fourth treatment, both treatment modalities showed comparable results. These results are also in line with reported long-term clearing rates for long-pulsed diode lasers and alexandrite lasers (84–85%) (14).

The current study has a number of limitations that warrant mention. First, due to the design, comparisons of efficacy and safety of the two lasers according to patient skin type were not possible. Additionally, hair density was not evaluated in a blinded way. Nevertheless, our automatic quantification of axillary hair density using TrichoScan software is still an improvement on the manual techniques employed by prior investigations. Although current guidelines suggest up to eight treatments for optimal results (15), most prior studies comparing the efficacy of alexandrite versus diode lasers tested the effects of only three to four treatments (14) as performed within this study.

Conclusion

In conclusion, the current study illustrates that the newly developed 755 nm diode laser suitable for HR and SHR procedures is as effective and safe as the traditional 755 nm alexandrite laser. Long term follow-up studies enrolling a sufficient number of patients of all suitable skin types are needed to confirm these preliminary findings.

Compared to published evidence, the new 755 nm diode laser system, although significantly faster, produces a hair clearance comparable to that of other diode laser systems immediately after four treatments (14). Additionally, treatment with the 755 nm diode laser was reported to be less painful.

Declaration of interest: The authors report no conflicts of interest. The authors alone are responsible for the content and writing of the paper.

Uwe Paasch received unrestricted research grants from and serves as consultant for Alma Lasers GmbH, Nürnberg, Germany.

References

1. Ibrahim OA, Avram MM, Hanke CW, Kilmer SL, Anderson RR. Laser hair removal. *Dermatol Ther.* 2011;24:94–107.
2. Anderson RR, Parrish JA. Selective photothermolysis: precise microsurgery by selective absorption of pulsed radiation. *Science.* 1983;220:524–527.
3. Altshuler GB, Anderson RR, Manstein D, Zenzie HH, Smirnov MZ. Extended theory of selective photothermolysis. *Lasers Surg Med.* 2001;29:416–432.
4. Dierickx CC, Grossman MC, Farinelli WA, Anderson RR. Permanent hair removal by normal-mode ruby laser. *Arch Dermatol.* 1998;134:837–842.
5. Kolster Verlag Marburg Bodendorf MO, Grunewald S, Paasch U. 2013. *Dermatologische Lasertherapie, Band 3 Epilationslaser* KVM Verlag, Berlin. 218 S.
6. Pai GS, Bhat PS, Mallya H, Gold M. Safety and efficacy of low-fluence, high-repetition rate versus high-fluence, low-repetition rate 810-nm diode laser for permanent hair removal - A split-face comparison study. *J Cosmet Laser Ther.* 2011;13:134–137.
7. Halachmi S, Lapidot M. Low-fluence vs. standard fluence hair removal: a contralateral control non-inferiority study. *J Cosmet Laser Ther.* 2012;14:2–6.
8. Koo B, Ball K, Tremaine AM, Zachary CB. A comparison of two 810 diode lasers for hair removal: Low fluence, multiple pass versus a high fluence, single pass technique. *Lasers Surg Med.* 2014;46:270–274.
9. Braun M. Permanent laser hair removal with low fluence high repetition rate versus high fluence low repetition rate 810 nm diode laser—a split leg comparison study. *J Drugs Dermatol.* 2009;8:s14–s17.
10. Hoffmann R. TrichoScan: combining epiluminescence microscopy with digital image analysis for the measurement of hair growth in vivo. *Eur J Dermatol.* 2001;11:362–368.
11. Gorgu M, Aslan G, Akoz T, Erdogan B. Comparison of alexandrite laser and electrolysis for hair removal. *Dermatol Surg.* 2000;26:37–41.
12. Lou WW, Quintana AT, Geronemus RG, Grossman MC. Prospective study of hair reduction by diode laser (800 nm) with long-term follow-up. *Dermatol Surg.* 2000;26:428–432.
13. Dierickx CC, Grossman MC, Farinelli WA, Anderson RR. Permanent hair removal by normal-mode ruby laser. *Arch Dermatol.* 1998;134:837–842.
14. Haedersdal M, Wulf HC. Evidence-based review of hair removal using lasers and light sources. *J Eur Acad Dermatol Venereol.* 2006;20:9–20.
15. Drosner M, Adatto M. Photo-epilation: guidelines for care from the European Society for Laser Dermatology (ESLD). *J Cosmet Laser Ther.* 2005;7:33–38.